

CLIA #: 31D2026917

PATIENT DEMOGRAPHICS

PATIENT INFORMATION:	PHYSICIAN INFORMATION:	SPECIMEN INFORMATION:
Patient, Test DOB: 1/1/1970 Gender/Age: M/52 SS#: UN:766985985	Test Physician, MD Test Practice 300 Columbus Circle Suite A, Edison, NJ 08837 866.909.PATH, Fax:908-272-1478	ACCESSION #: TS22-000X1 PROCEDURE DATE: 11/14/2022 DATE RECEIVED: 11/14/2022 REPORTED ON: 12/1/2022

CLINICAL INFORMATION

CLINICAL HISTORY: Abnormal liver enzymes, Percutaneous liver biopsy.

FINAL DIAGNOSIS

A: Liver, Biopsy:
- Hepatic tissue with Steatohepatitis and stage 3 fibrosis; NAS 6/8 (see comment).

Comment: The biopsy consists of 5 cores of hepatic tissue, adequate for evaluation. The hepatocytes show marked macrovesicular steatosis, involving 70% of the hepatocytes, glycogenation of nuclei and prominent ballooning change associated with neutrophilic inflammation and abundant Mallory's hyaline. The portal tracts show mild chronic inflammation comprising of lymphocytes. Focal lobular activity composed of lymphocytes is seen. Pericellular, portal and bridging fibrosis is seen. No interface activity, aggregates of plasma cells, cholestasis, necrosis, acidophil bodies, ground glass hepatocytes or prominent pigment deposition is seen. The bile ducts appear unremarkable.

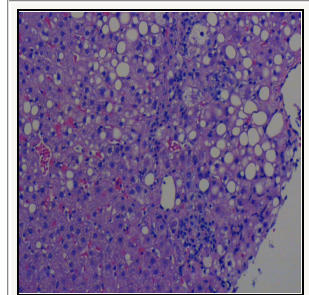
The trichrome stain highlights pericellular, portal and bridging fibrosis (stage 3 fibrosis). The PASD stain is negative for alpha 1 antitrypsin like globules. The iron stain is negative for hemosiderin. The CK19 stain shows focal bile duct proliferation.

The clinical history of diabetes and elevated transaminases has been reviewed.

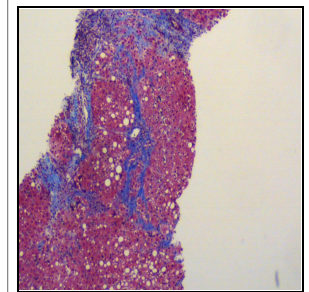
Semi quantitative scoring
NASH CRN Lobular: 1 (0-3)
NASH CRN Ballooning: 2 (0-2)
NASH CRN Steatosis: 3 (0-3)
NASH CRN Fibrosis: 3 (0-4)

NAFLD Activity score (NAS): 6 (0-8)

Scoring Reference
NASH CRN; Kleiner et al; Hepatology 2005; 41: 1313-1321



Steatohepatitis, H&E



Stage 3 Fibrosis, Trichrome

GROSS EXAMINATION

A: "Patient, Test, Liver" received in formalin are five soft tan tissue fragments measuring 0.2, 0.2, 0.3, 0.5 and 0.5 cm in length. The specimen is entirely submitted in a single cassette.

MICROSCOPIC EXAMINATION

Tissue blocks: 1

Physician: Test Physician, MD

Electronically signed out by: Reema Jaffar, MD

● 300 Columbus Circle, Suite A, Edison, NJ 08837 ● Tel: 1-866-909-PATH ● Fax: 908-272-1478

BILLING CODES

CPT

88307
88313 X 3
88342

ICD-10

K75.81; N/A
Date of Procedure: 11/14/2022

ELECTRONICALLY SIGNED OUT BY

Pathologist:



Reema Jaffar, MD