

CLIA #: 31D2026917

*Consulting Pathologist: Test Pathologist*

**PATIENT DEMOGRAPHICS**

PATIENT INFORMATION:	PHYSICIAN INFORMATION:	SPECIMEN INFORMATION:
<b>Patient, Test</b> DOB: 1/1/1945 Gender/Age: F/74 SS#: UN:206796836	<b>Test Physician</b> Test Practice 300 Columbus Circle, Suite A, Edison, NJ 08837 866.909.PATH, Fax:908-272-1478	ACCESSION #: <b>TS22-00223</b> PROCEDURE DATE: 5/6/2022 DATE RECEIVED: 5/7/2022 REPORTED ON: 5/8/2022

**CLINICAL INFORMATION**

**CLINICAL HISTORY:** LMP Date: 12/19/15, ICD-10: N92.0  
**OPERATIVE PROCEDURE:** Colposcopy & Curettage

**FINAL DIAGNOSIS**

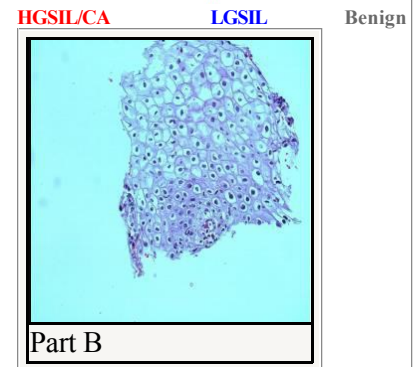
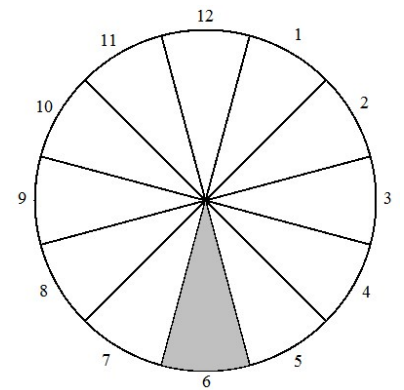
**A: Cervix at 6 O'Clock, Colposcopy:**

- Benign cervical tissue with reactive squamous epithelium
- Negative for dysplasia.( P16 and Ki 67 immunostaing)
- No transformation zone is present.

**B: Endocervix, Curettage:**

- Low grade squamous intraepithelial lesion, LGSIL (mild dysplasia, CIN I), minute fragment
- Strips of squamous epithelium and benign endocervical tissue.
- Immunostain for Ki67 shows increased proliferative activity and immunostain for p16 is diffusely positive supporting the above diagnosis.

**BIOPSY SITE MAP**



**GROSS EXAMINATION**

**A:** "Patient, Test, 6:00" received in formalin is a soft tan tissue fragment measuring 0.5 x 0.4 x 0.2 cm in greatest dimension. The specimen is entirely submitted in a single cassette.  
**B:** "Patient, Test, ECC" received in formalin is a soft tan tissue fragment measuring 0.4 x 0.4 x 0.2 cm in greatest dimension. The specimen is entirely submitted in a single cassette.

**BILLING CODES**

**CPT**  
88305 X 2

**ICD-10**  
N87.0

**Date of Procedure: 5/6/2022**

**ELECTRONICALLY SIGNED OUT BY**

**Pathologist:**

*Test Pathologist*

Test Pathologist