

CLIA #: 31D2026917

Consulting Pathologist: Test Pathologist, MD

PATIENT DEMOGRAPHICS

PATIENT INFORMATION:	PHYSICIAN INFORMATION:	SPECIMEN INFORMATION:
Patient, Test DOB: 1/1/1960 Gender/Age: M/59 SS#: UN:174000249	Test Physician Test Practice 300 Columbus Circle, Suite A, Edison, NJ 08837 866.909.PATH, Fax:908-272-1478	ACCESSION #: TS22-02002 PROCEDURE DATE: 3/12/2022 DATE RECEIVED: 3/13/2022 REPORTED ON: 3/14/2022

CLINICAL INFORMATION

CLINICAL HISTORY: Rectal hard mass

FINAL DIAGNOSIS

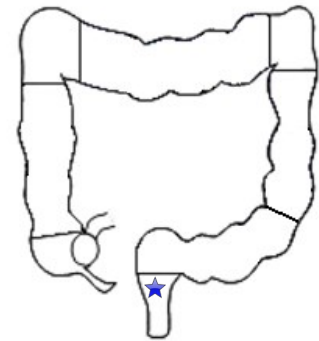
A: RECTUM, BIOPSY:

- Well differentiated neuroendocrine tumor consistent with Carcinoid.

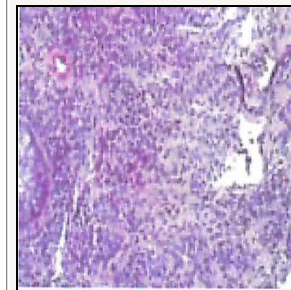
Comments:

- The tumor is mainly submucosal with few nests seen in the mucosa. The tumor has an acinar pattern and shows mild nuclear pleomorphism. No mitosis or necrosis are identified. The tumor is 0.4 cm in its greatest diameter and is seen at the cauterized margin of resection.
- Immunostains confirm the above diagnosis (Synaptophysin, Neuron specific enolase, Chromogranin and Pankeratin are positive).
- The distinction of benign or malignant carcinoid is based on the absence of metasis

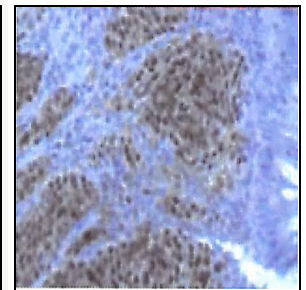
SITE MAP



★ Site Marker



H&E



HSE-IHC

GROSS EXAMINATION

A: "Patient, Test, Rectum" received in formalin is a soft tan tissue fragment measuring 0.2 x 0.3 x 0.3 cm. The specimen is entirely submitted in a single cassette.

BILLING CODES

CPT 88305 88342 88341 X 3	ICD-10 D3A.026 Date of Procedure: 3/12/2022
---	---

ELECTRONICALLY SIGNED OUT BY

Pathologist: *Test Pathologist*
 Test Pathologist, MD